

LOWER LIMB VENOUS DUPLEX SCAN REPORT

Consultant: Mr Sarutzi S

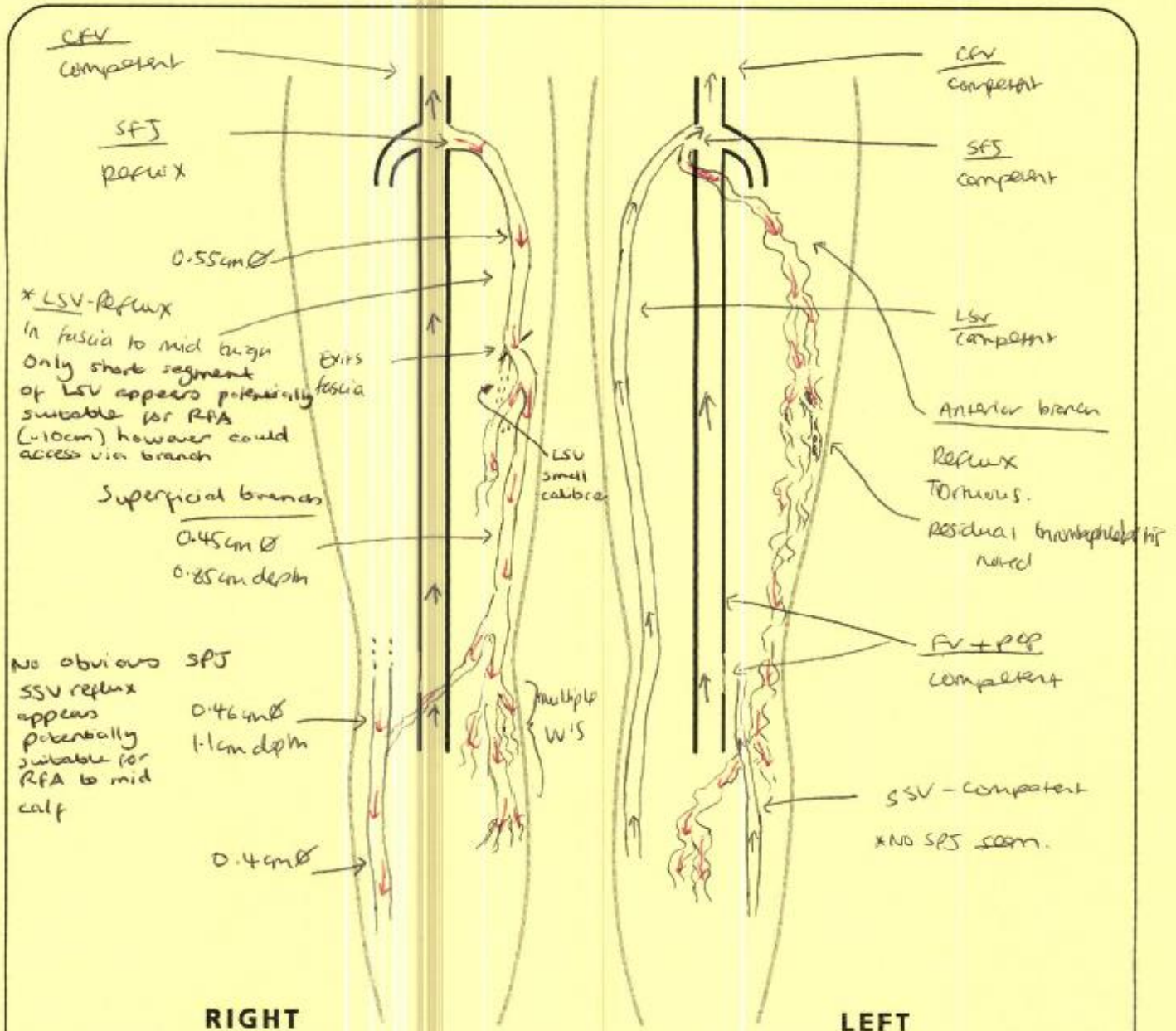
Dept: VSV

Clinical History:

Hospital: GH

Comments:

B/L venous duplex



SIGNED:

[Signature]

CLINICAL VASCULAR SCIENTIST

PRINT NAME:

S. Farn / H. Unna

DATE:

28/2/22

Image Quality:

GOOD

☒

POOR

Level 1
Glenfield Hospital
Tel: 0116 258 5440

LOWER LIMB VENOUS DUPLEX SCAN REPORT

Consultant: Mr Vainas

Dept: F&D

Clinical History:

Hospital: GH

Comments:

(R) venous duplex

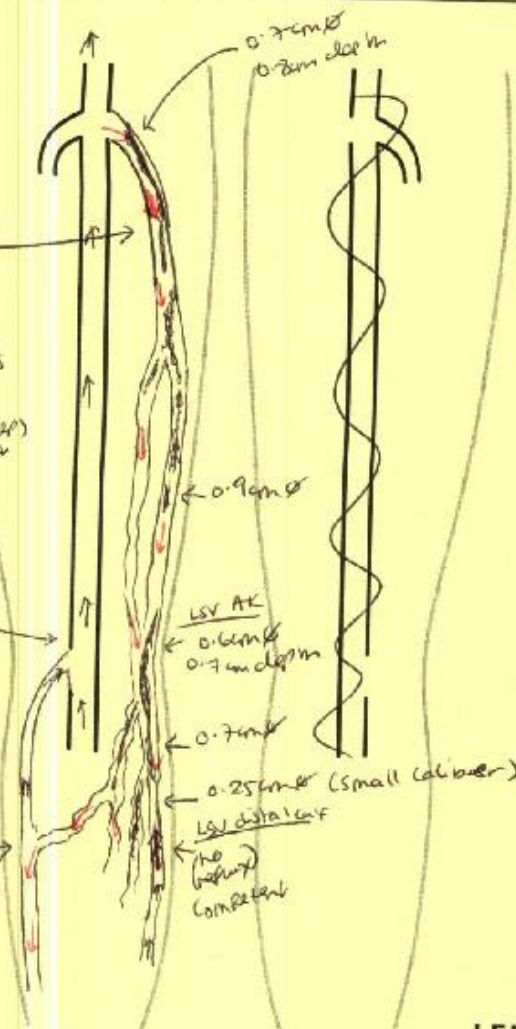
CPV, PV + popv
competent

LSV
Reflex from SFJ
down to proximal calf
Residual thrombophlebitis
noted, 1.4 cm
length away from crv (deep)
vein

SPJ + SSV popv
competent

SSV mid calf
Reflex due to
incompetent vein from LSV
0.5 cm x
0.7 cm deep

RIGHT



LEFT

SIGNED: S. Maslen

PRINT NAME:

S. Maslen

MASLEN

CLINICAL VASCULAR SCIENTIST

DATE:

3/3/22

Image Quality:

GOOD ☐ ☒ POOR

LOWER LIMB VENOUS DUPLEX SCAN REPORT

Consultant: Mr McCarmy

Dept: V&U

Clinical History:

Hospital: CH

Comments:

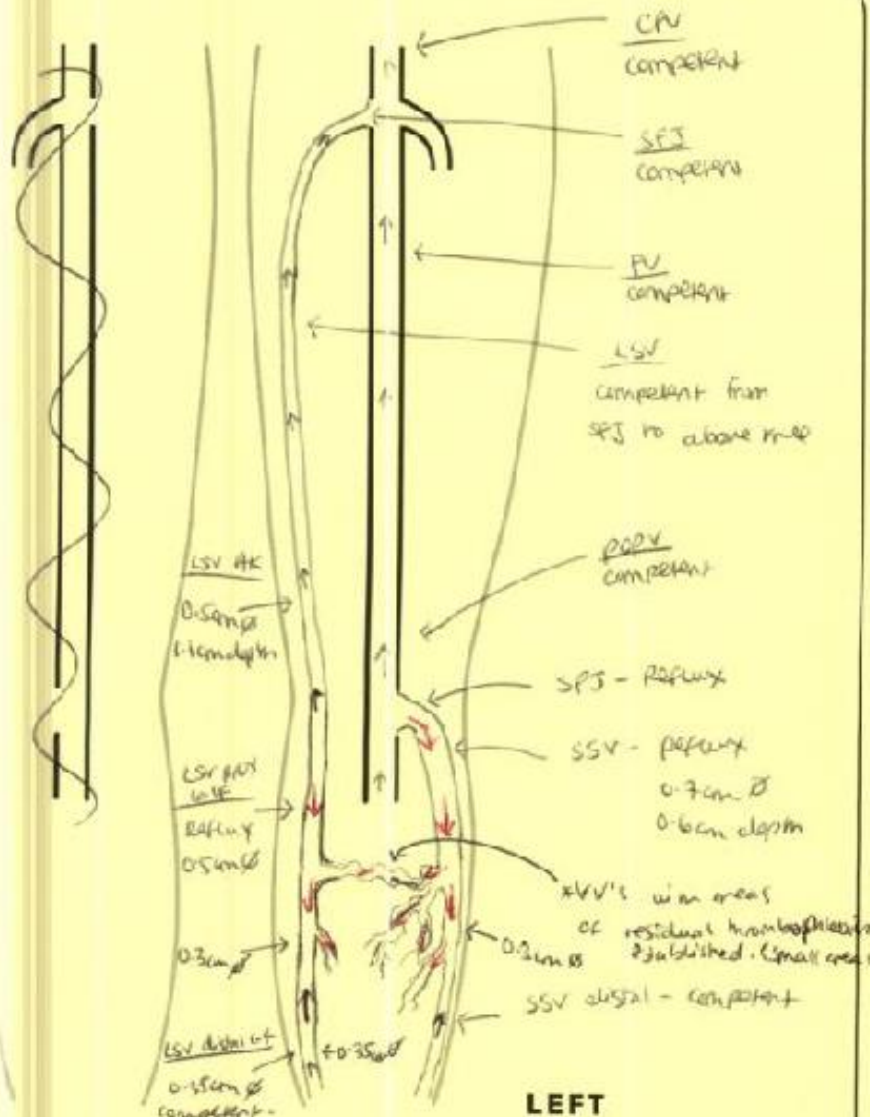
Ⓛ venous duplex

Left leg

+ no obvious evidence of DVT noted in this study.

+ No acute thrombus noted in SSV + LSV.

+ Chronic/post-thrombotic areas of thrombophilia noted in UV's in mid calf. (see diagram).



SIGNED:

CLINICAL VASCULAR SCIENTIST

PRINT NAME:

DATE:

28/2/22

Image Quality:

GOOD

☒

☐

POOR

Level 1
Glenfield Hospital
Tel: 0116 258 5440

LOWER LIMB VENOUS DUPLEX SCAN REPORT

Consultant: Mr Davies

Dept: VSU

Clinical History:

Hospital: GH

Comments:

Ⓡ Leg venous duplex

CFV + FV
Competent

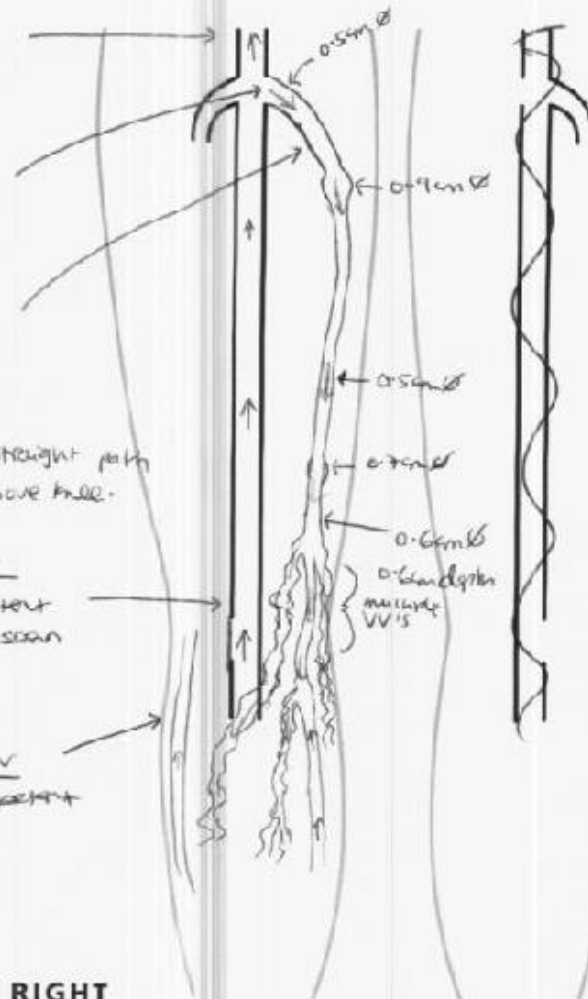
SFS
Reflux

ISV
+ Reflux

x in fascia
*Extends in straight path
down to above knee.

PPV
Competent
SFS not scan

SSV
Competent



RIGHT

LEFT

SIGNED:

CLINICAL VASCULAR SCIENTIST

PRINT NAME:

DATE:

Image Quality:

GOOD ☐ ☒ POOR ☐

DUS DUPLEX SCAN REPORT

Dept: VLSU

Hospital: C.H.

② UV's scan




Image Quality:

GOOD ☐ ☒ POOR

LOWER LIMB VENOUS DUPLEX SCAN REPORT

Consultant: Mr Bewley

Dept: VSU

Clinical History:

Hospital: Cliff

Comments: b/l venous scan

CFV + FV
Competent

SFJ
Competent

LSV
Competent

PopV + SSV + SPJ
Competent

mid calf w/r
reflux

RIGHT

CFV + FV
Competent

SFJ
Competent

LSV
competent to
prox calf

PopV + SSV + SPJ
Competent

LSV mid calf

Mild incompetent
(↑ leg reflux)
? due to soft tissue
oedema.

LEFT

SIGNED: *S. Forster*

CLINICAL VASCULAR SCIENTIST

PRINT NAME:

S. Forster LIA SACE

DATE:

08/03/22

Image Quality:

GOOD ☐ ☒ POOR

LOWER LIMB VENOUS DUPLEX SCAN REPORT

Consultant: R SMD

Dept: VSV

Clinical History:

Hospital: GH

Comments:

B/L venous duplex
 B recurrent UV's
 C primary UV's

CFV + SFV
 Competent

LSV
 Competent

PopV
 Competent

Recurrent
 SPS + SSV
 Reflux

Chronic area of non-occlusive thrombophlebitis

RIGHT

SFV + CFV
 Competent

SFV
 Reflux

LSV prox
 Competent

Anterior vein branch
 Reflux + Tortuosity

LSV mid - Reflux
 O-band due to UV's from anterior branch

PopV - Competent

Gracilis - SSV for junction
 Competent

SSV mid calf
 Reflux due to incompetent part
 O-band O-Symptoms

LEFT

SSVAK
 O-Symptoms
 12cm deep in fascia
 straight in nature

O-Symptoms
 O-Tenodesis

FVE
 mid Reflux
 < 1sec
 O-band

SIGNED: *Richard Sharpe*

CLINICAL VASCULAR SCIENTIST

PRINT NAME: *S. Sharpe R. A. Sharpe*

DATE: *17/1/22*

Image Quality:

GOOD ☐ ☒ POOR ☐

Level 1
Glenfield Hospital
Tel: 0116 258 5440

NHS Trust

LOWER LIMB VENOUS DUPLEX SCAN REPORT

Consultant: Mr Davies

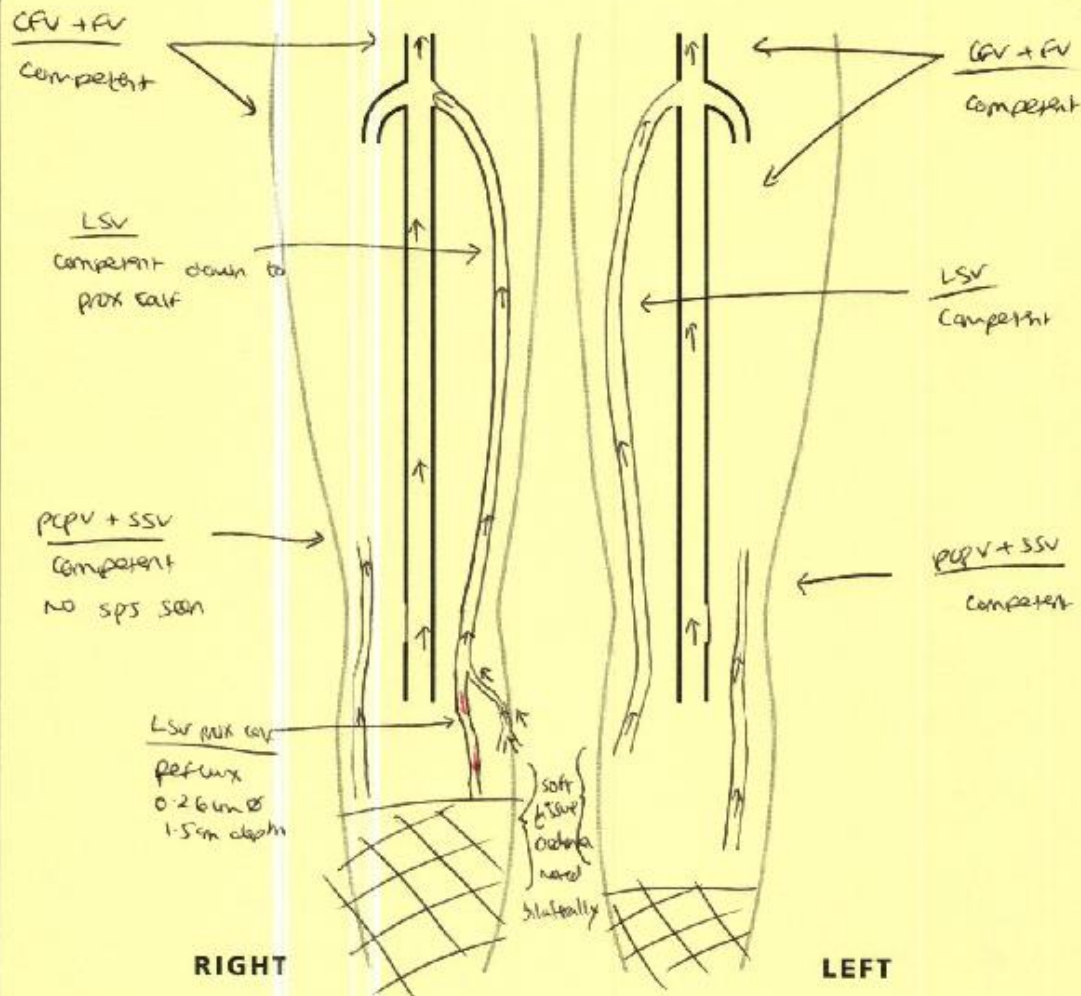
Dept: VALS

Clinical History:

Hospital: GH

Comments:

B/L venous duplex



SIGNED: *[Signature]*

CLINICAL VASCULAR SCIENTIST

PRINT NAME: S. Foran

DATE: 21/3/22

Image Quality:

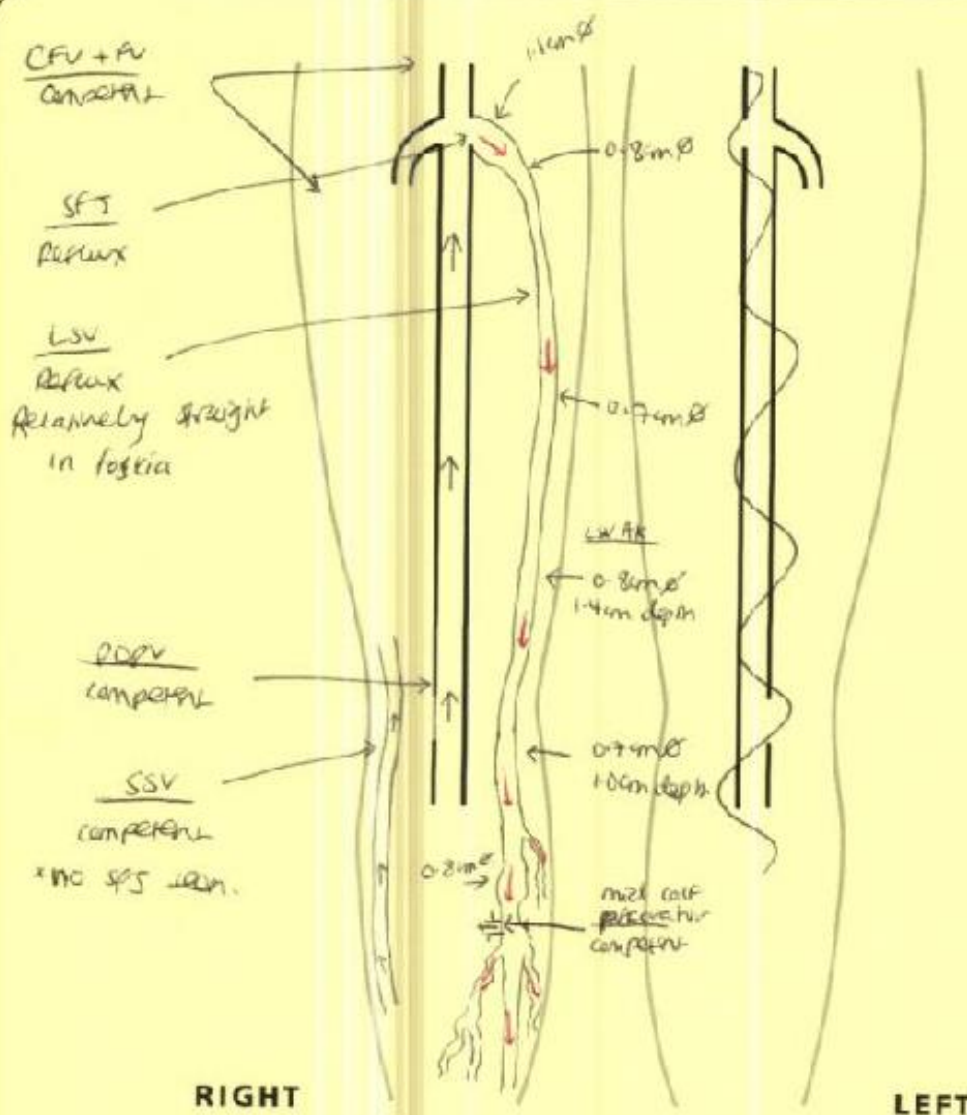
GOOD ☐ ☒ POOR

Level 1
Glenfield Hospital
Tel: 0116 258 5440

LOWER LIMB VENOUS DUPLEX SCAN REPORT

Consultant: Mr McMahon
Clinical History:
Comments: (R) VVS

Dept: VSV
Hospital: GH



SIGNED: *S. Forth*

CLINICAL VASCULAR SCIENTIST

PRINT NAME: S. Forth

DATE: 22/03/22

Image Quality:

GOOD ☐ ☒ POOR

LOWER LIMB VENOUS DUPLEX SCAN REPORT

Consultant: Mr Kay

Dept: VSU

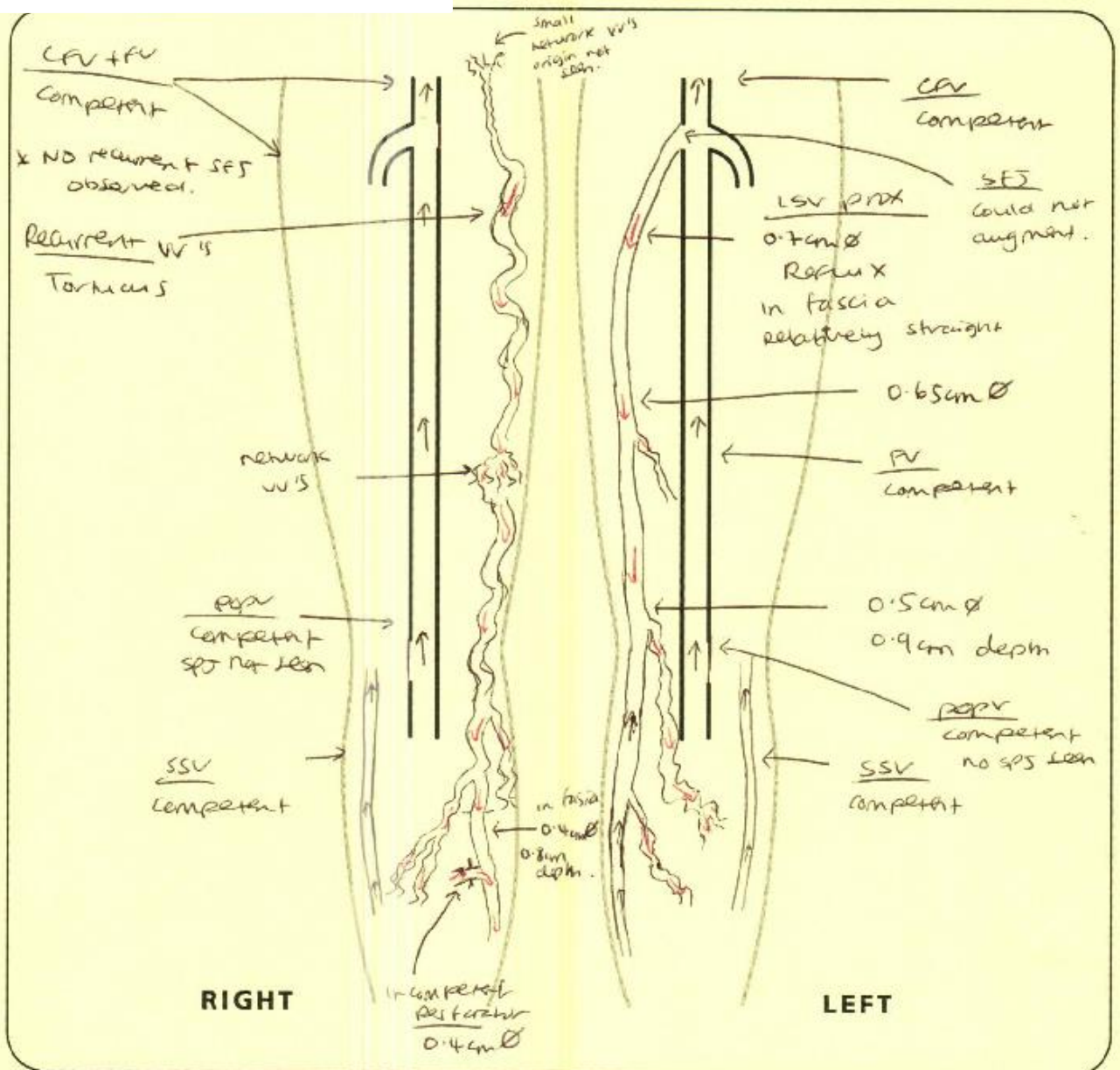
Clinical History:

Hospital: GH

Comments:

B/L venous duplex

* previous @ high bp



SIGNED:

CLINICAL VASCULAR SCIENTIST

PRINT NAME:

S. Forster / Nunes

DATE:

24/3/22

Image Quality:

GOOD

☒

POOR

POOR

LOWER LIMB VENOUS DUPLEX SCAN REPORT

Consultant: Mr Davis

Dept: Vasc

Clinical History:

Hospital: CH

Comments:

B/L VVUS duplex

CFV + FV
competent

LSV
competent

POP + SPS
competent

SSV
competent

RIGHT

mid calf
short length
of incompetence
not in LSV.

CFV + FV
competent

CFV + FV
competent

LSV
competent

POP
competent
SPS not seen

SSV
competent

LEFT

SIGNED: *[Signature]*

CLINICAL VASCULAR SCIENTIST

PRINT NAME: S. J. Smith

DATE: 29/3/22

Image Quality:

GOOD ☐ ☒ POOR

LOWER LIMB VENOUS DUPLEX SCAN REPORT

Consultant: *RSMD*

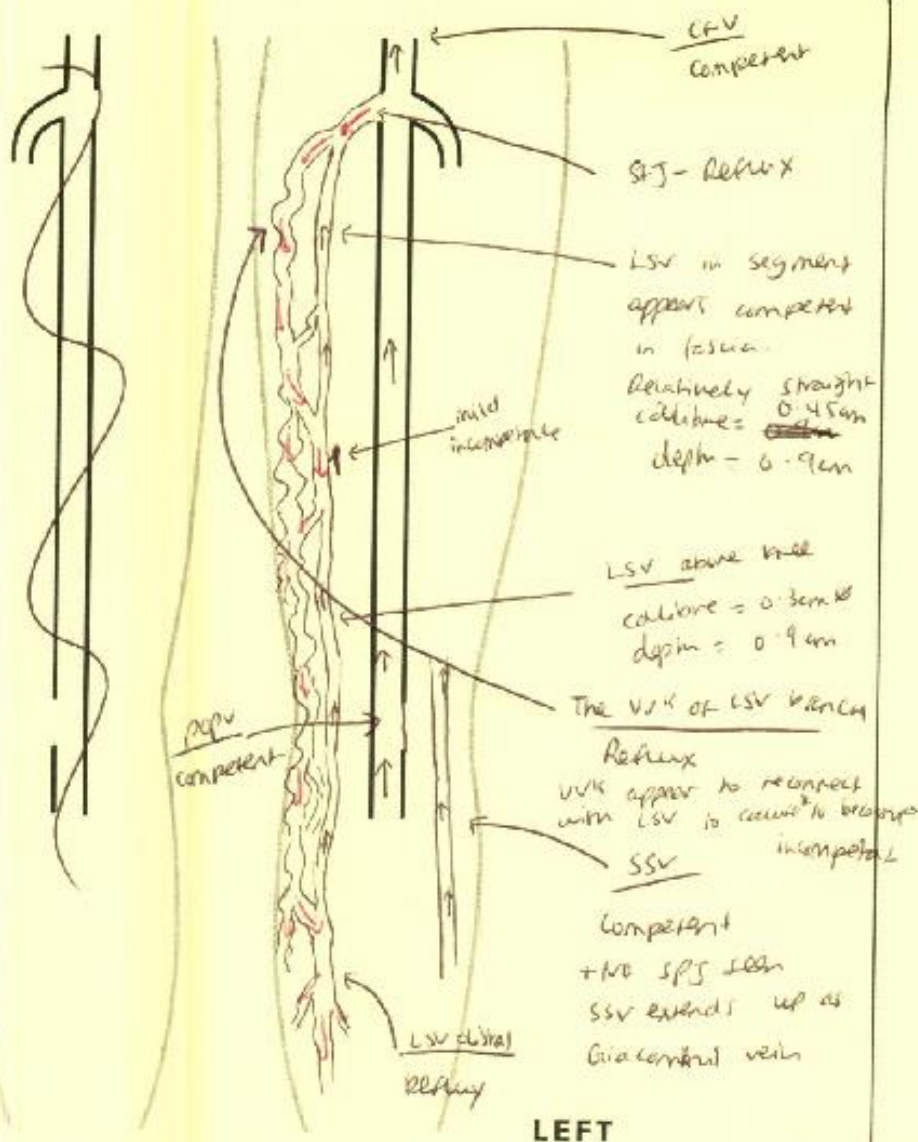
Dept: *WVS VSV*

Clinical History:

Hospital: *GH*

Comments:

② Leg venous duplex



RIGHT

LEFT

SIGNED:

S. Farah

CLINICAL VASCULAR SCIENTIST

PRINT NAME:

S. Farah

DATE:

30/3/22

Image Quality:

GOOD

☒

☐


☐

POOR

Dept: Vas &

Hospital: CH

④ venous duplex



Level 1
Glenfield Hospital
Tel: 0116 258 5440

DUPLEX SCAN REPORT

Consultant: Mr Varnas

Dept:

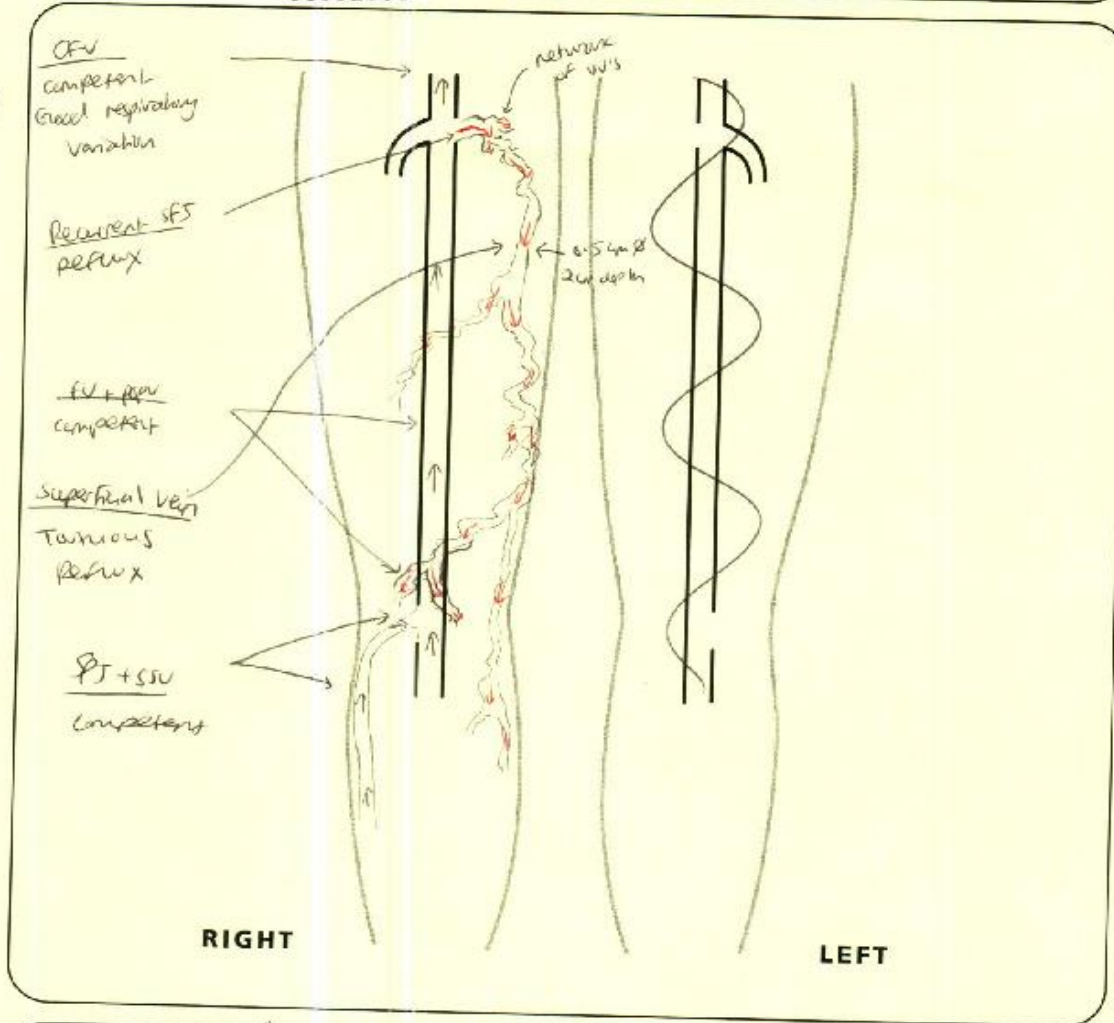
Clinical History:

Hospital: CH

Comments:

② venous duplex
Previous B/L vv procedures

U4551338



SIGNED: *[Signature]* Sunderman

CLINICAL VASCULAR SCIENTIST

PRINT NAME: S-farmer S. Sunderman

DATE: 10/12/1

Image Quality:

GOOD ☐ ☒ POOR

LOWER LIMB VENOUS DUPLEX SCAN REPORT

Consultant: MK

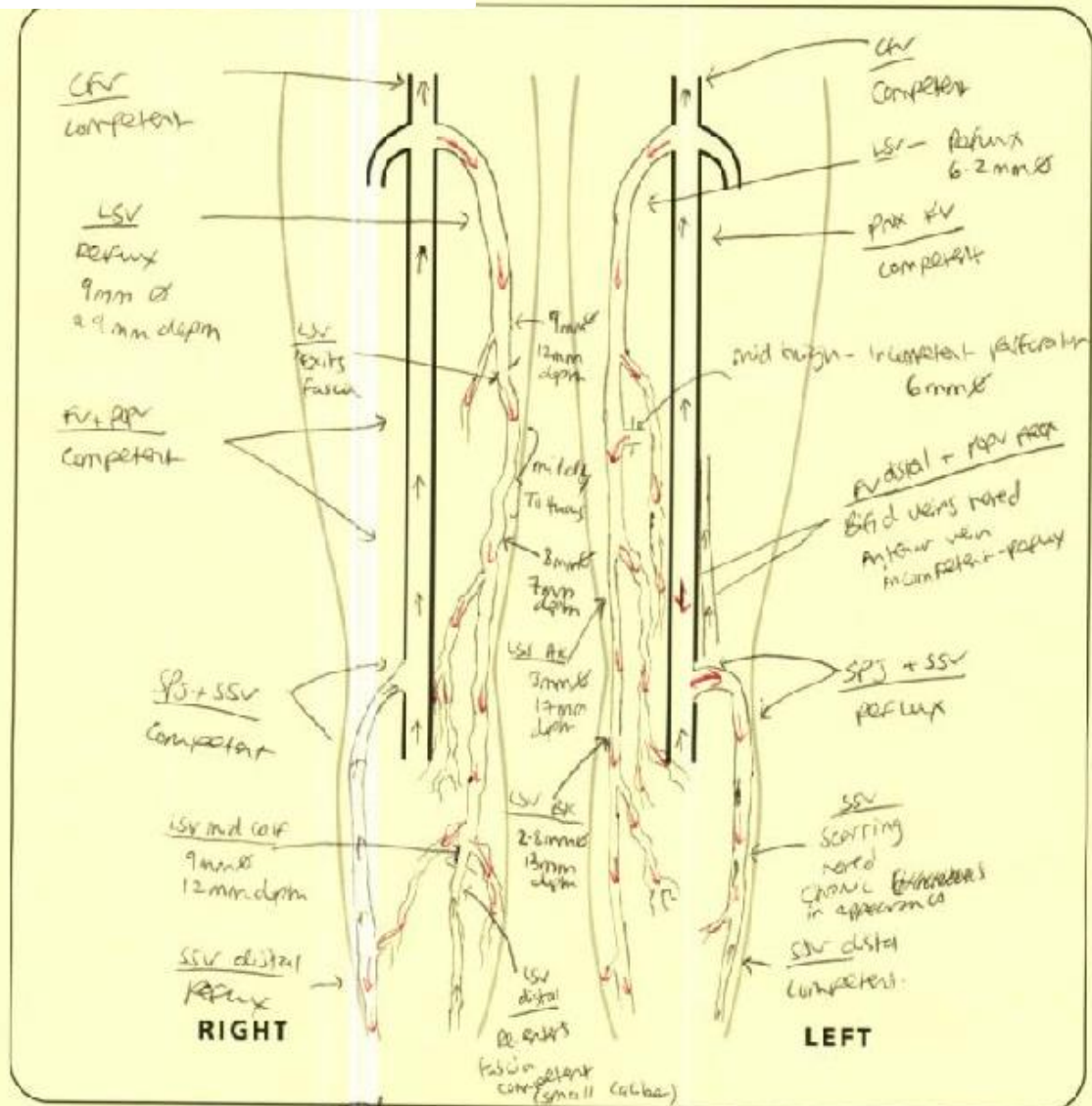
Dept: VSU

Clinical History:

Hospital: CHT

Comments:

B/L venous duplex



SIGNED:

S. Jagan

CLINICAL VASCULAR SCIENTIST

PRINT NAME:

DATE:

14/12/21

Image Quality:

GOOD

☒

POOR

LOWER LIMB VENOUS DUPLEX SCAN REPORT

Consultant: ND

Dept: V&U

Clinical History:

Hospital: CGH

Comments:

Ⓡ venous duplex

CFV + FV
Competent

Anterior branch uv
13mm &
21mm depth

Large Anterior branch
uv

Reflex
Chronic areas
noted of scarring
? from prev phlebitis

perp
competent
no sps seen

uv prox calf
Reflex

SSV
Competent

10mm depth
3mm &

5mm &
4mm depth

RIGHT

LEFT

SIGNED: S. Sarah LIA SHARPE

CLINICAL VASCULAR SCIENTIST

PRINT NAME: S. Sarah LIA SHARPE

DATE: 15/12/21

Image Quality:

GOOD ☐ ☒ POOR

VASCULAR STUDIES UNIT

University Hospitals of Leicester **NHS**
NHS Trust

Level 1
Glenfield Hospital
Tel: 0116 258 5440

LOWER LIMB VENOUS DUPLEX SCAN REPORT

Consultant: ND

Dept: VSW

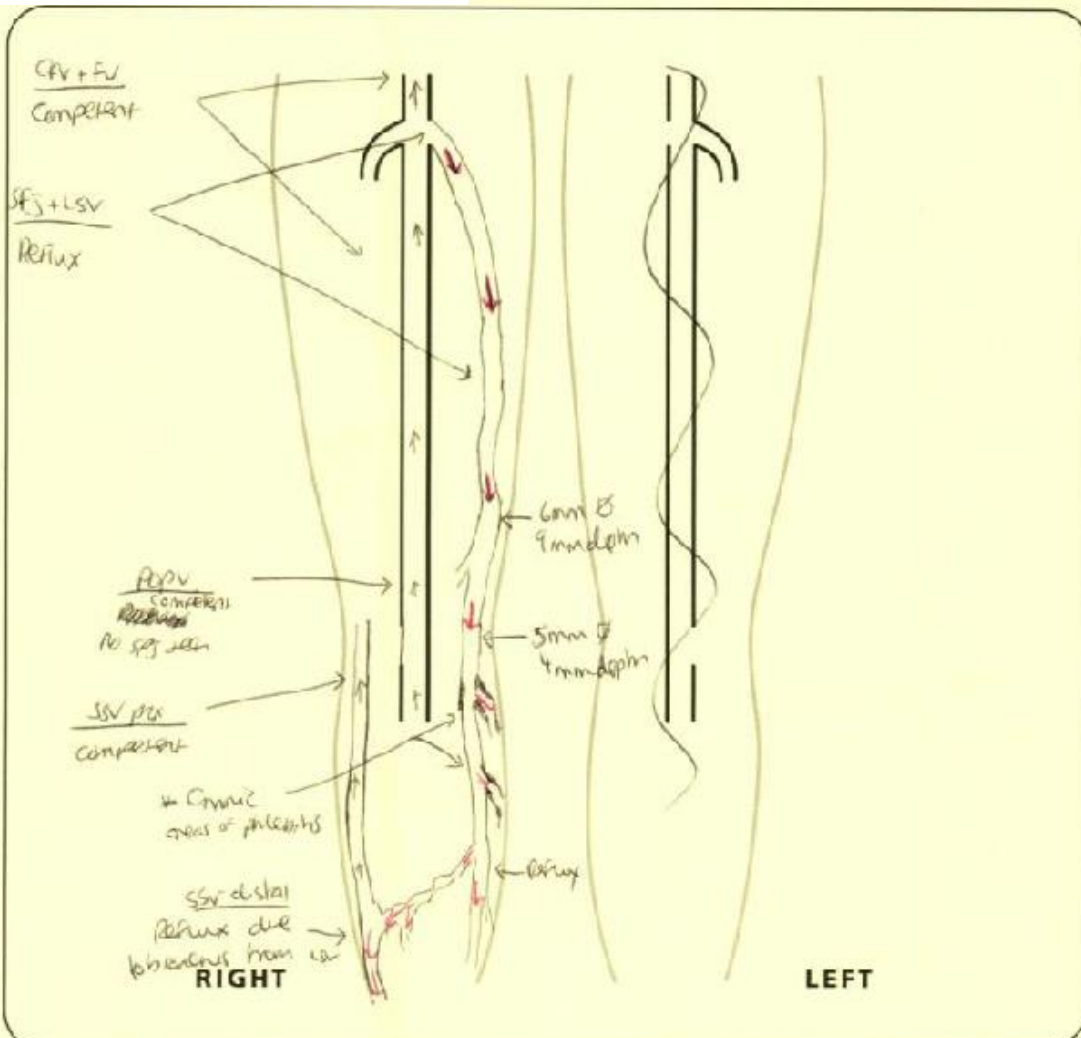
Clinical History:

Hospital: CH

Comments:

(R) venous duplex

(R) WIF



SIGNED: *S. Sharpe*

CLINICAL VASCULAR SCIENTIST

PRINT NAME:

S. Sharpe

DATE:

15/12/21

Image Quality:

GOOD

☒

☐

☐

POOR

VENOUS DUPLEX SCAN REPORT

Consultant: Mr Vamas

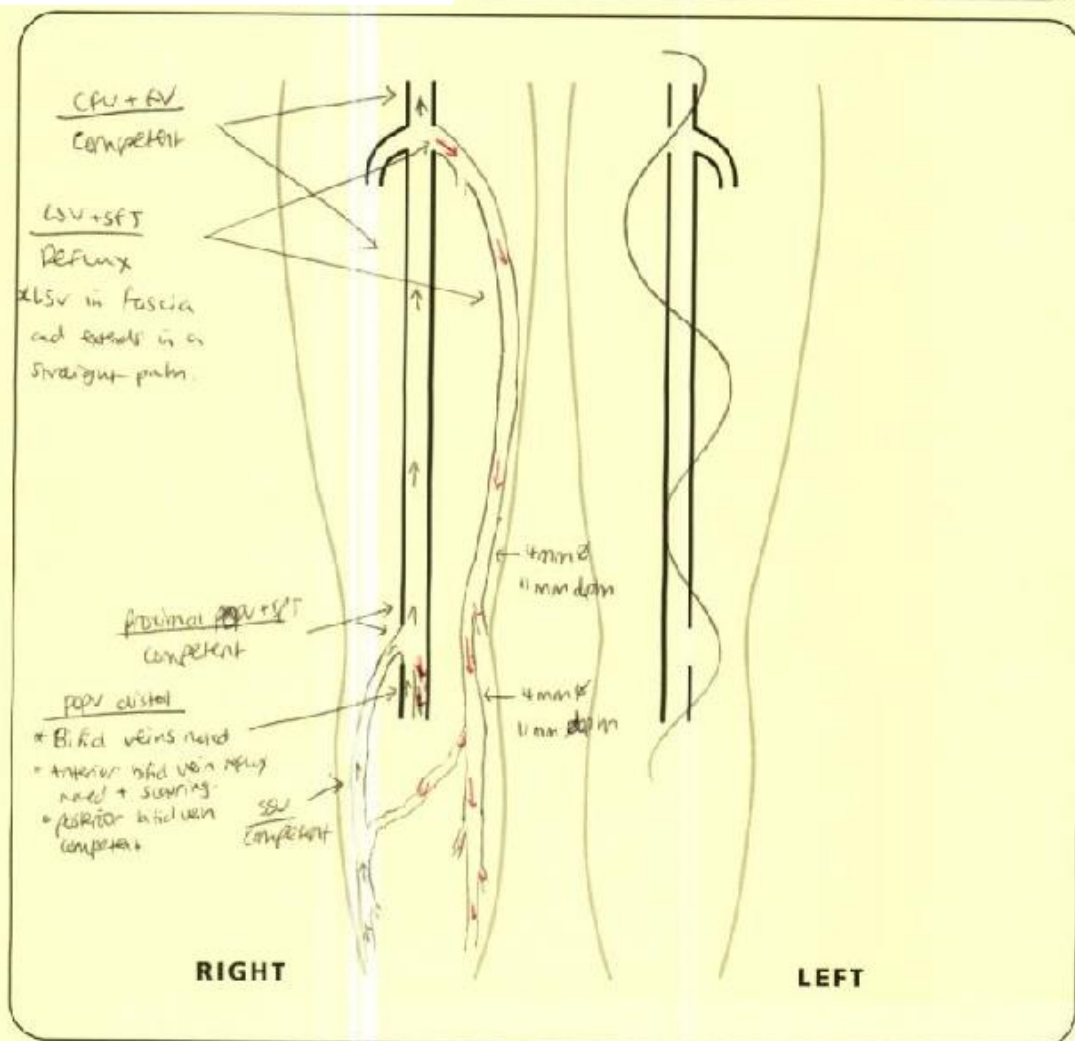
Dept: V&S

Clinical History:

Hospital: GH

Comments:

Ⓡ venous duplex



SIGNED: *[Signature]*

CLINICAL VASCULAR SCIENTIST

PRINT NAME: S. Foster / Hannah Lines

DATE: 22/12/24

Image Quality:

GOOD ☐ ☒ POOR

Level 1
Glenfield Hospital
Tel: 0116 256 5440

NHS Trust

LOWER LIMB VENOUS DUPLEX SCAN REPORT

Consultant: ND

Dept: VCU

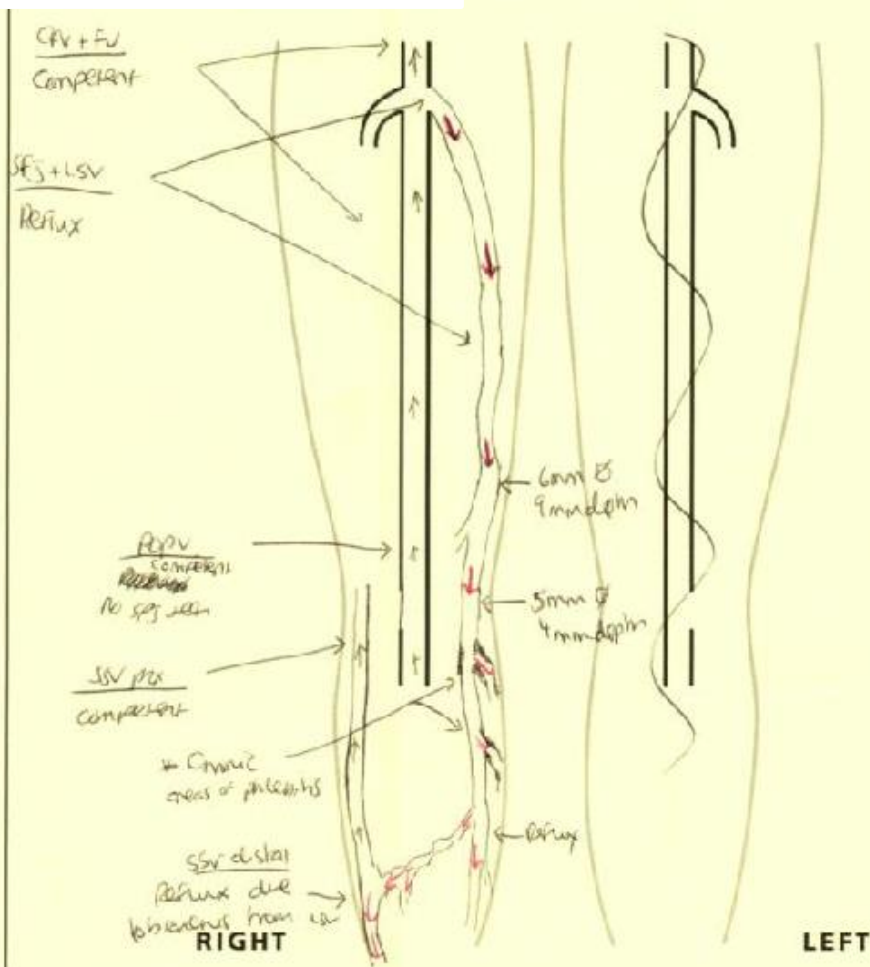
Clinical History:

Hospital: CH

Comments:

(R) venous duplex

(R) WTR



SIGNED: *S. Lohape*

CLINICAL VASCULAR SCIENTIST

PRINT NAME:

S. Lohape BA SHARPE

DATE:

15/12/21

Image Quality:

GOOD

☒

POOR

Level 1
Glenfield Hospital
Tel: 0116 258 5440

NHS Trust

LOWER LIMB VENOUS DUPLEX SCAN REPORT

Consultant: Mr Vanaas

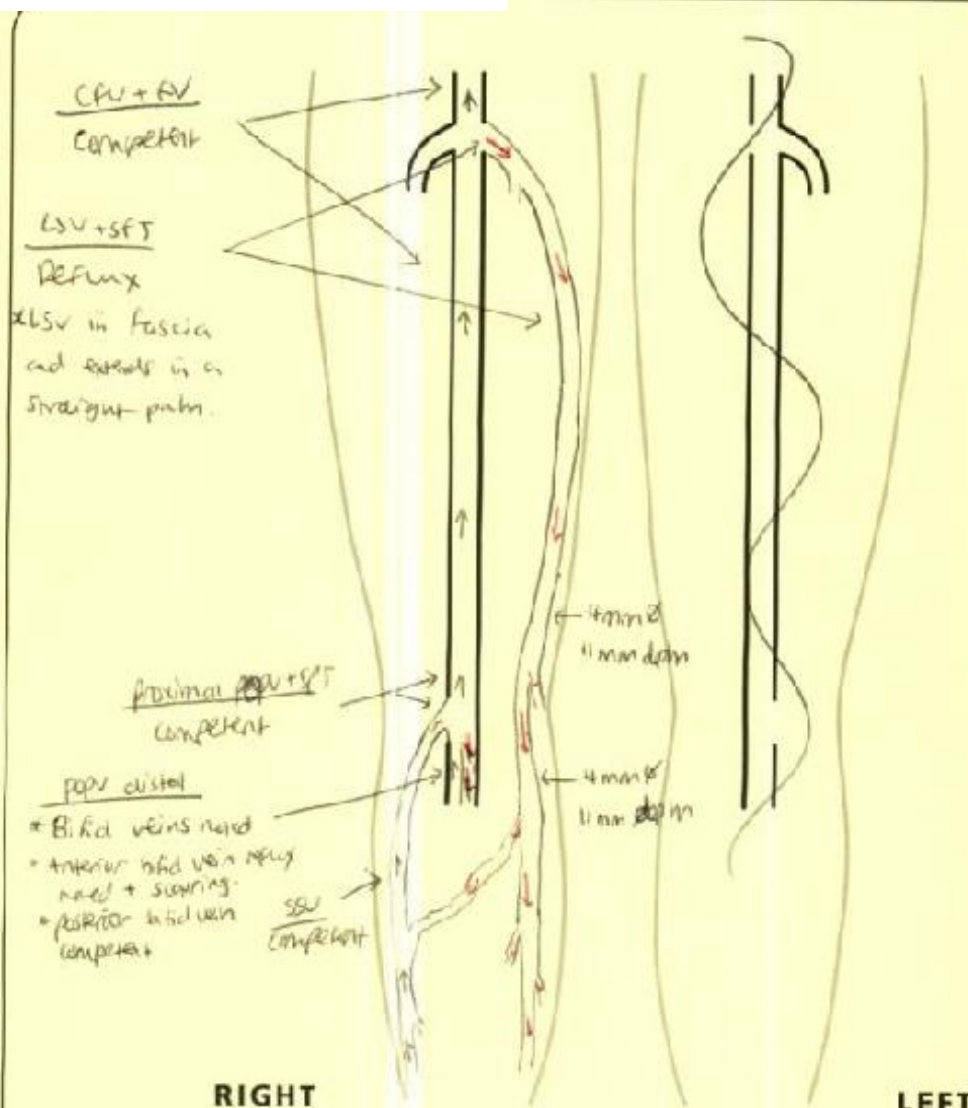
Dept: V&U

Clinical History:

Hospital: GH

Comments:

(R) venous duplex



SIGNED: *[Signature]*

CLINICAL VASCULAR SCIENTIST

PRINT NAME:

S. Lewis / Hannah Lines

DATE:

22/12/21

Image Quality:

GOOD

☐

☒

☐

POOR

VASCULAR STUDIES UNIT

Level 1
Glenfield Hospital
Tel: 0116 258 5440

University Hospitals of Leicester **NHS**
NHS Trust

VASCULAR STUDIES TEST REPORT

Consultant: Mr Ray Dept: W023

Clinical History: Hospital: GH

(R) Arm vein marking.

Right Arm Vein
Marking.

Right cephalic vein was marked on patient skin. Vein diameters
~~have~~ ranged from 3-4 mm ϕ as previously reported.

SIGNED: [Signature]

CLINICAL VASCULAR SCIENTIST

PRINT NAME: S. Leach

DATE: 24/3/22 TIME:

Image Quality:

GOOD ☐ ☒ ☐ POOR

Malvern1016-060751

Level 1,
Glenfield Hospital
Tel: 0116 255 5440

VASCULAR STUDIES TEST REPORT

Consultant: TV Dept: VSU
Clinical History: Hospital: Cash

② perforator vein markings

Left leg vein.

* Left leg incompetent perforator vein marked
on patient mid thigh. Perforator ~~seen~~^{marked} at a depth
of 1 cm and a diameter of 0.8 cm Ø.

SIGNED: [Signature] CLINICAL VASCULAR SCIENTIST
PRINT NAME: S. Smith DATE: 7/3/22 TIME:

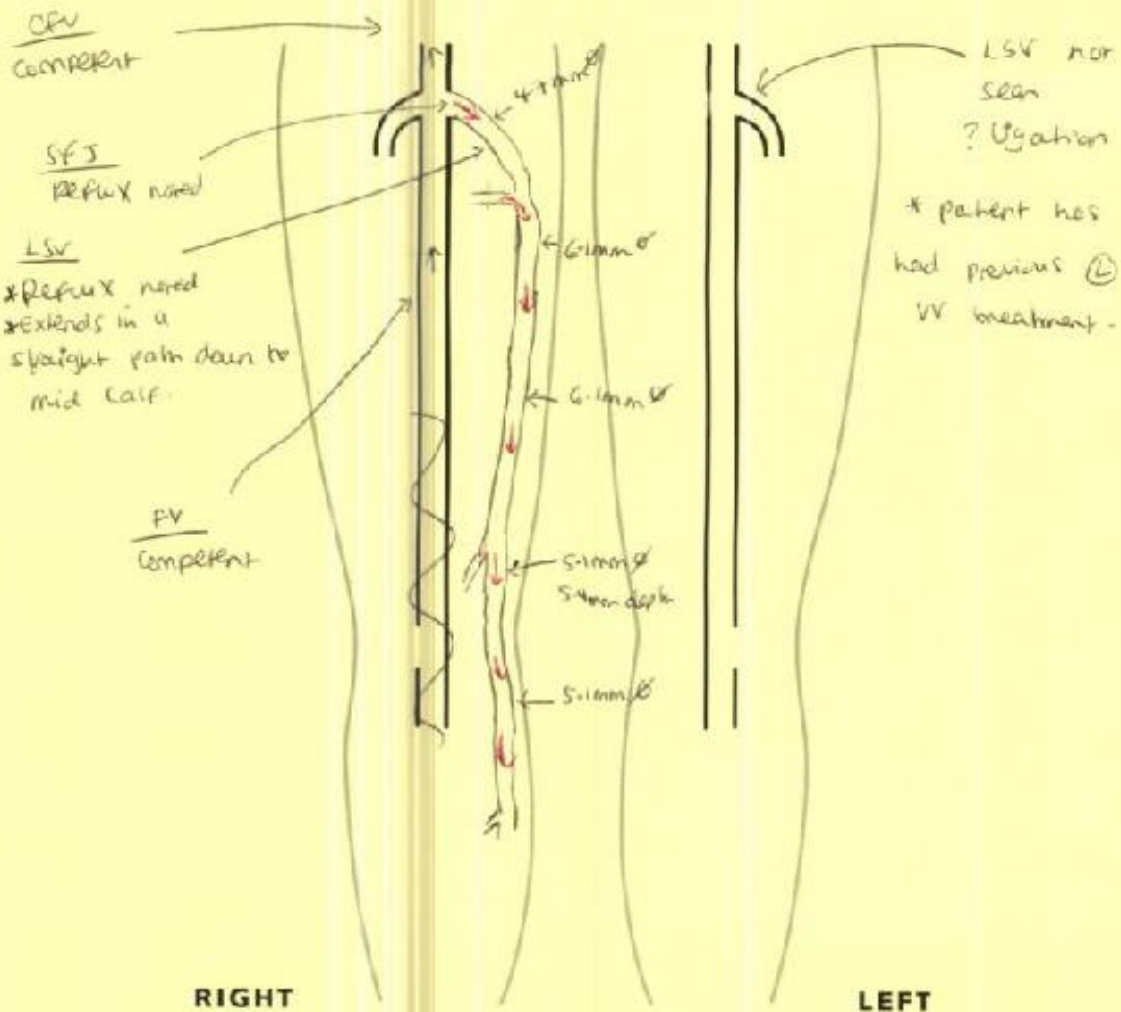
Image Quality:
GOOD ☐ ☒ POOR

Level 1
Glenfield Hospital
Tel: 0116 258 5440

NHS Trust

LOWER LIMB VENOUS DUPLEX SCAN REPORT

Consultant: Mr Hadjnikolaou Dept: W34
Clinical History: Hospital: GH
Comments: Bil vein mapping



SIGNED: *[Signature]*

CLINICAL VASCULAR SCIENTIST

PRINT NAME: *S. Farah*

DATE: *17/2/22*

Image Quality:

GOOD ☐ ☒ POOR

VASCULAR STUDIES UNIT

University Hospitals of Leicester NHS Trust

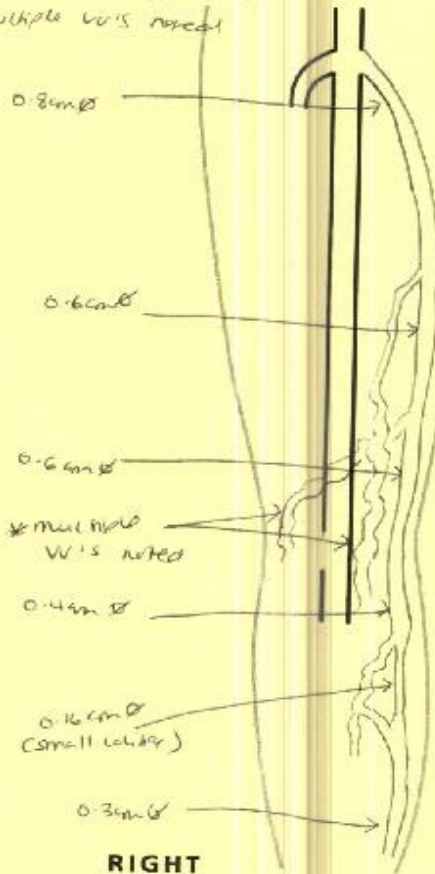
Level 1
Glenfield Hospital
Tel: 0116 258 5440

LOWER LIMB VENOUS DUPLEX SCAN REPORT

Consultant: MR L Venidas Hodgkinson Dept: WD 31
Clinical History: Hospital: G11
Comments:

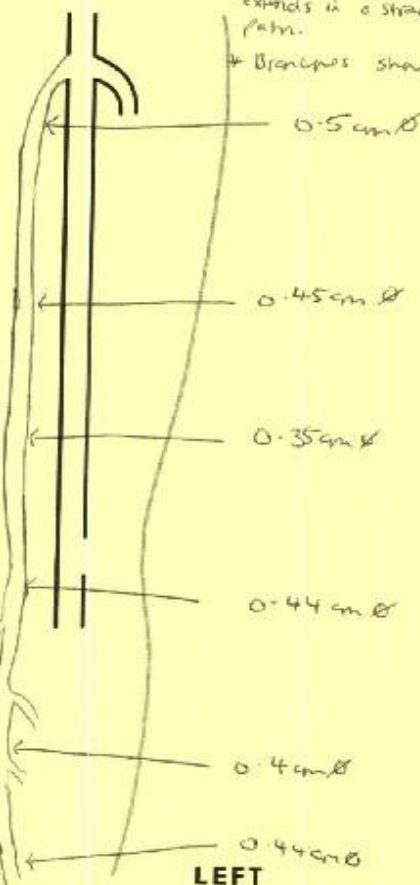
B/L vein mapping

* (R) LSV in fascia
extends in straight path
+ multiple V's noted



RIGHT

* LSV in fascia
extends in a straight
path.
+ Branches shown.



LEFT

SIGNED: *[Signature]*
PRINT NAME: S. Fera

CLINICAL VASCULAR SCIENTIST
DATE: 28/1/22

Image Quality: ☒ GOOD ☐ POOR

LOWER LIMB VENOUS DUPLEX SCAN REPORT

Consultant: Dr Vella

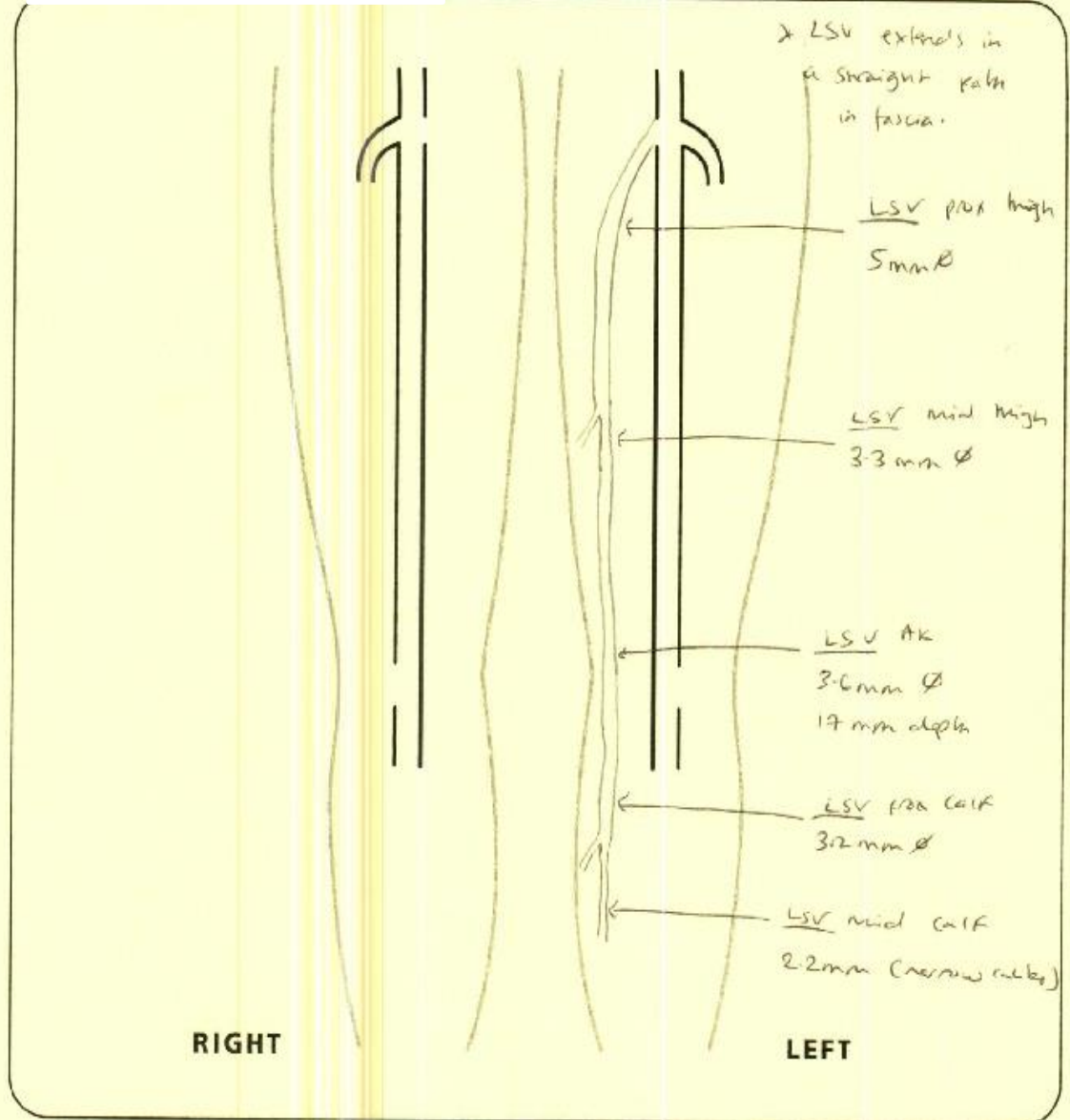
Dept: WP 29

Clinical History:

Hospital: GH

Comments:

① ven mapping



SIGNED:

[Signature]

CLINICAL VASCULAR SCIENTIST

PRINT NAME:

S-forer

DATE:

7/1/22

Image Quality:

GOOD

☐

☒

☐

☐

POOR